










## Department of Oral Medicine and Radiology-Special cases

SL.NO	NAME	AGE	DIAGNOSIS	INTRAORAL POTOGRAPHS
1	MALLESH	31/M	HOMOGENOUS LEUKOPLKIA	
2	PRAGATHI	30/F	BENIGN MIGRATORY GLOSSITIS	
3	MALLIKARJUN	36/M	PLAQUE TYPE OF LICHEN PLANUS	




## Department of Oral Medicine and Radiology-Special cases

SL.N O	NAME	AGE/ SEX	DIAGNOSIS	INTRAORAL PHOTOGRAPHS
4	DODDABASAVA	40/M	HEALED LICHEN PLANUS	
5	ISMAIL KHAN	54/M	IRRITATIONAL FIBROMA	
6	GOPAL KRISHNA	63/M	SQUAMOUS CELL CARCINOMA	

**Department of Oral Medicine and Radiology-Special cases**

<p>7</p>	<p>MD.KAIF</p>	<p>21/M</p>	<p><b>TRAUMATIC ULCER AND HOMOGENOUS LEUKOPLKIA</b></p>	
<p>8</p>	<p>ANJAMMA</p>	<p>40/F</p>	<p><b>RETICULAR LICHEN PLANUS</b></p>	
<p>9</p>	<p>RENUKAMMA</p>	<p>50/F</p>	<p><b>INFLAMMATO RY GINGIVAL ENLARGEMENT</b></p>	

**Department of Oral Medicine and Radiology-Special cases**

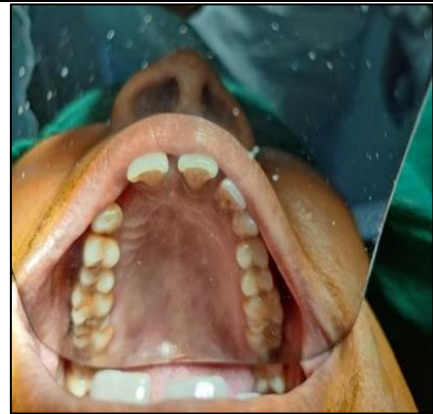<p>10</p>	<p>JAYAPPA</p>	<p>35/M</p>	<p><b>SMOKERS MELANOSIS</b></p>	
<p>11</p>	<p>VALI</p>	<p>35/M</p>	<p><b>HOMOGENOUS LEUKOPLAKIA</b></p>	
<p>12</p>	<p>ANJINAMMA</p>	<p>38/F</p>	<p><b>CHRONIC DENTOALVEOLA R ABSCESS</b></p>	

13

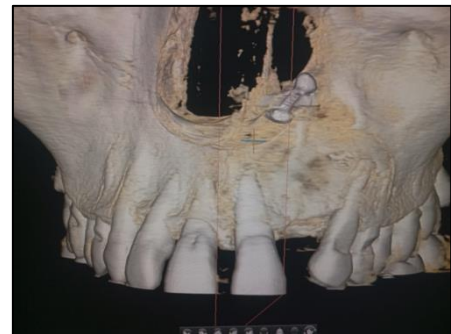KHANISH  
FATHIMA

45/F

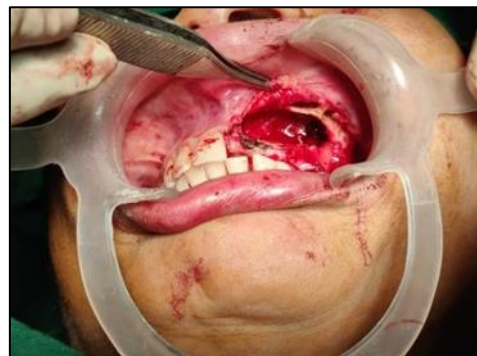**RADICULAR  
CYST**



**Intraoral photograph**





**Cbct**



**Enucleation of cyst**

**Department of Oral Medicine and Radiology-Special cases**

<p>14</p>	<p>SRINATH</p>	<p>50/M</p>	<p><b>HOMOGENOUS LEUKOPLAKIA</b></p>	 A clinical photograph showing the buccal mucosa (inner cheek) of a patient. A white, well-demarcated, homogenous plaque is visible on the buccal mucosa. The plaque has a slightly wrinkled or leathery appearance. A dental mirror is used to examine the plaque, and a dental probe is visible at the bottom right.
<p>15</p>	<p>JAYSHREE</p>	<p>38/F</p>	<p><b>Carcinoma of left lateral border of tongue</b></p>	 A clinical photograph showing the tongue of a patient. A red, ulcerated lesion is visible on the lateral border of the tongue. The lesion is irregular in shape and has a central area of ulceration. The surrounding mucosa appears normal.

## **Department of Oral Medicine and Radiology-Special cases**

---

<b>SI NO</b>	<b>SPECIAL CASES</b>
1	Homogenous Leukoplakia
2	Benign migratory glossitis
3	Plaque type of Lichen planus
4	Healed Lichen planus
5	Irritational fibroma
6	Squamous cell carcinoma
7	Traumatic ulcer and Homogenous Leukoplakia
8	Reticular Lichen planus
9	Inflammatory gingival enlargement
10	Smokers melanosis
11	Homogenous leukoplakia
12	Chronic dentoalveolar abscess
13	Radicular cyst
14	Homogenous Leukoplakia
15	Carcinoma of left lateral border of tongue